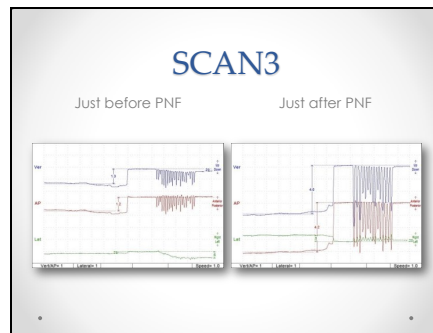



28



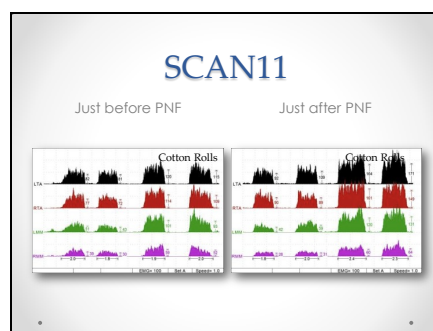
This is Scan 3 data. The amount of freeway space increased.

29



This is Scan 9 data. The EMG level of the left masseter and temporalis decreased.

30



This is comparison of Scan 11. Occlusal force is increased with use of cotton rolls. This patient has so-called dual bite, which apparently caused deformation of the condyles. Use of cotton rolls seems to decrease the extent of compression applied to condyle, and also facilitation with traction and compression of joints seems to increase occlusal force in function.