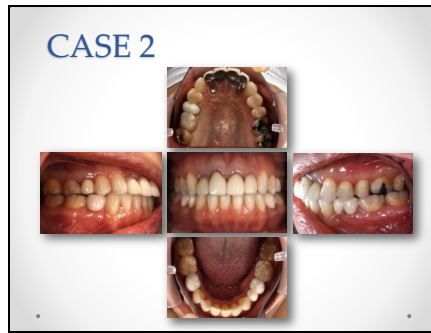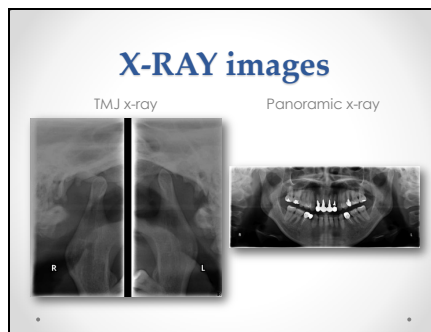


25




This is a 39 year old woman. This is intra-oral finding.

26



These are TMJ and panoramic x-rays. It is noted that the form of the right and the left condyles is different.

27



This is comparison of Scan 2 data before and after PNF. Like the first case, the time difference is about 5 minutes.