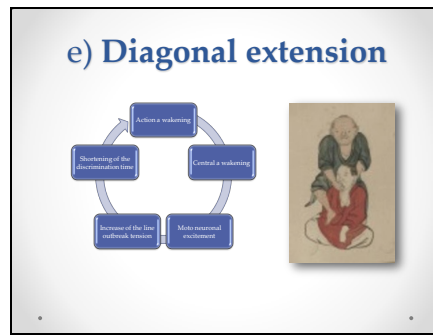


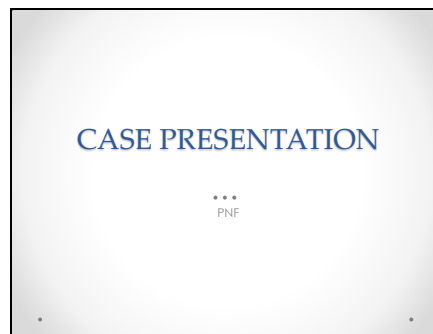
13



**Factors of facilitation**

e) Diagonal extension

14



In my clinic, PNF is used, as an integral part of rehabilitation, to improve the mandibular functions. I will present 2 cases with clinical films of the main PNF procedures applied to the maxillo-facial area and K7 data before and after PNF procedures.

15



These are frontal and whole body photos just before PNF. The patient is a Japanese American, living in Hawaii.